

Circulation

JOURNAL OF THE AMERICAN HEART ASSOCIATION



Wolff-Parkinson-White Syndrome and Accessory Pathways

James Kulig and Bruce A. Koplan

Circulation 2010;122:e480-e483

DOI: 10.1161/CIRCULATIONAHA.109.929372

Circulation is published by the American Heart Association, 7272 Greenville Avenue, Dallas, TX 75214

Copyright © 2010 American Heart Association. All rights reserved. Print ISSN: 0009-7322. Online ISSN: 1524-4539

The online version of this article, along with updated information and services, is located on the World Wide Web at:

<http://circ.ahajournals.org/cgi/content/full/122/15/e480>

Subscriptions: Information about subscribing to *Circulation* is online at
<http://circ.ahajournals.org/subscriptions/>

Permissions: Permissions & Rights Desk, Lippincott Williams & Wilkins, a division of Wolters Kluwer Health, 351 West Camden Street, Baltimore, MD 21202-2436. Phone: 410-528-4050. Fax: 410-528-8550. E-mail:
journalpermissions@lww.com

Reprints: Information about reprints can be found online at
<http://www.lww.com/reprints>



Wolff-Parkinson-White Syndrome and Accessory Pathways

James Kulig, PA-C; Bruce A. Koplan, MD, MPH



The heart has 4 chambers that pump blood. The 2 upper chambers are the right and left atria, and the 2 lower chambers are the right and left ventricles. The heart also has an electric system that directs the coordinated beating of these 4 chambers. A schematic drawing of the normal heart structure and electric system (red arrows) is shown in Figure 1. A normal electric impulse originates in an area of the upper right atrium called the sinus (SA) node, and an ordinary electric activity of the heart is referred to as normal sinus rhythm. In normal sinus rhythm, an electric impulse is generated by the SA node, and that electricity spreads through the right and left atria, directing these chambers to beat. On an electrocardiogram (ECG; bottom of Figure 1), the electric activity from the atria is seen as a small rounded deflection called a P wave. The same electric impulse then passes through a small area of tissue between the atria and ventricles called the atrioventricular (AV) node and then down through the ventricles. On the ECG, the electric activity from the ventricles results in a larger deflection called the R wave or QRS complex.

Because the AV node is small, there is not enough electric activity to cause a deflection in the ECG. Therefore, the time spent by the electric impulse traveling through the AV node is represented on the ECG by a flat interval called the PR interval. In a normal heart, the AV node is a gatekeeper of sorts in that it is the only pathway for electricity that communicates from the upper chambers (atria) to the lower chambers (ventricles). The combination of electric impulses from the SA node to the atria, then through the AV node, and down to the ventricles results in 1 heartbeat. In summary, the electric activity on the ECG starts with a small deflection that results from atrial electric activity (the P wave), followed by a flat section resulting from electric activity through the AV node (the PR interval), followed by a larger deflection that results from electric activity from the ventricles (the R wave or QRS complex).

What Is an Accessory Pathway or Bypass Tract?

Some people are born with an extra piece of heart muscle tissue that connects directly between the atria and the ventricles, bypassing the AV node al-

together. This abnormal piece of muscle is referred to as a bypass tract or an accessory pathway (Figure 2). This extra piece of tissue can serve as a passageway for the electric signals between the atria and ventricles and allow electric activity in the ventricles to occur immediately after electric activity in the atria without having to wait for the electric impulse to travel through the AV node. In this situation, the ECG may not have much of a flat PR interval but instead may have the P wave (from atrial activity) right up against the R wave (from ventricular activity), with the R wave beginning with an up-slope referred to as a delta wave (Figure 2). This delta wave results from electric activity traveling over the accessory pathway and bypassing the AV node.

Some people with an accessory pathway have a normal ECG at baseline because the accessory pathway is electrically active only when there is a fast, racing heartbeat (tachycardia) described below. Therefore, some people with accessory pathways can have completely normal ECGs like the one seen in Figure 1. This is referred to as a concealed accessory pathway.

The information contained in this *Circulation* Cardiology Patient Page is not a substitute for medical advice, and the American Heart Association recommends consultation with your doctor or healthcare professional.

From the Cardiovascular Division, Brigham and Women's Hospital, Boston, Mass.

Correspondence to Dr Bruce A. Koplan, Brigham and Women's Hospital, Cardiovascular Division, 75 Francis St, Boston, MA 02446. E-mail bkoplan@partners.org

(*Circulation*. 2010;122:e480-e483.)

© 2010 American Heart Association, Inc.

Circulation is available at <http://circ.ahajournals.org>

DOI: 10.1161/CIRCULATIONAHA.109.929372


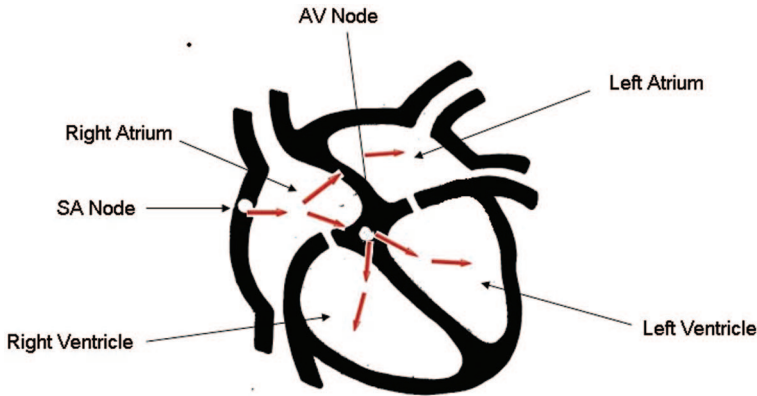


Figure 1. A schematic drawing of the 4 chambers of the heart (atria and ventricles) with the normal electric system (SA node and AV node) is shown in the top image. The bottom image shows a normal ECG. The P wave results from electric activity in the atria. The R wave results from electric activity in the ventricles. See text for further details.

How Does an Accessory Pathway Cause a Fast Heartbeat (Tachycardia)?

Not all patients with accessory pathways have fast heartbeats. Some people

with a delta wave on their ECG caused by an accessory pathway will never have a problem with a fast heartbeat. In others, a rapid heartbeat (tachycardia) can sometimes suddenly

occur. The 3 different types of tachycardias associated with accessory pathways are shown in Figure 3. The most common type (Figure 3A) results from an electric circuit that travels from the atria through

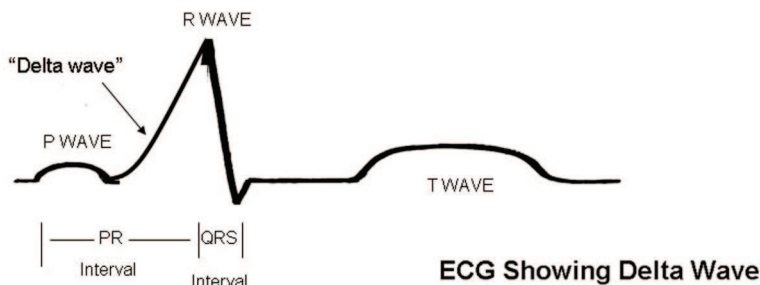
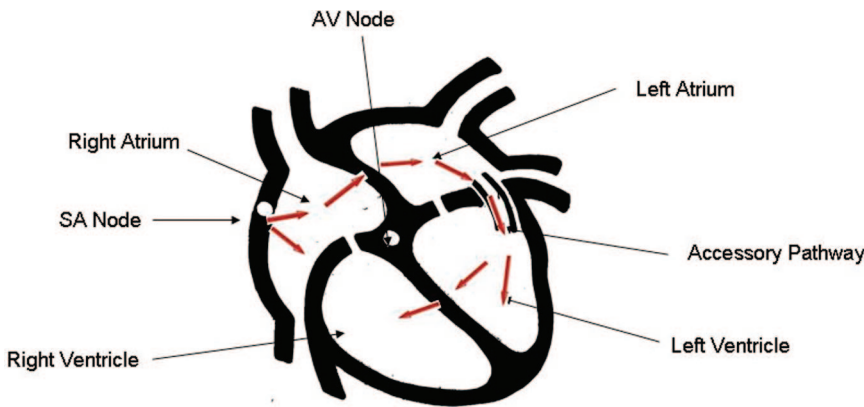
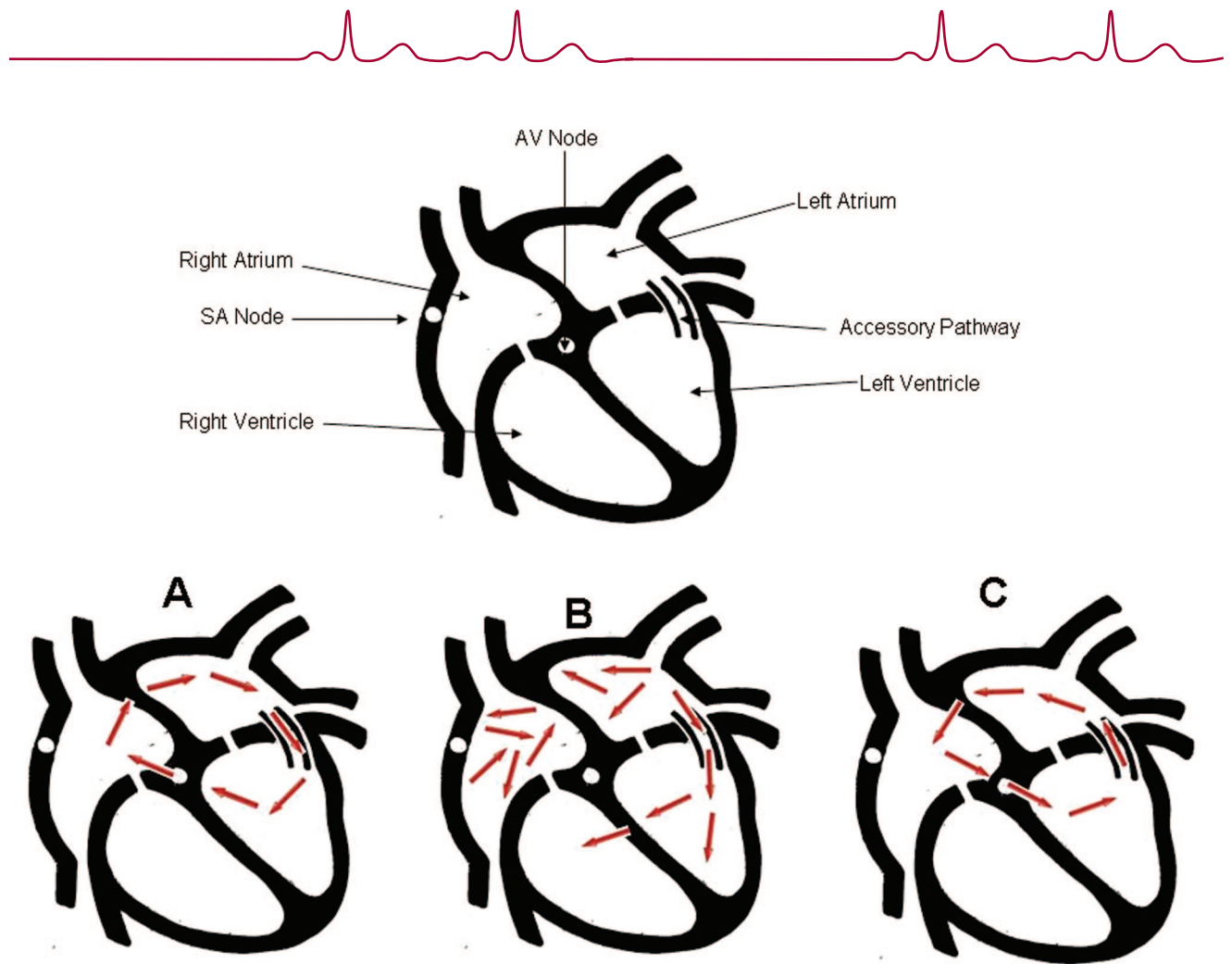


Figure 2. Image of the heart with an accessory pathway that bypasses electric activity through the AV node (top). An ECG is also shown with a delta wave between the P wave and R wave that results from electric activity through the bypass tract. See Figure 1 and text for further details.



Tachycardia in Patients with an Accessory Pathway

Figure 3. Schematic drawings of the heart showing 3 different types of tachycardias (fast heartbeats) that can result from an accessory pathway. See text for details.

the AV node to the ventricles, then backward through an accessory pathway to the atria, and then back through the same circuit over and over again. Because this is a circuit that reenters itself and involves the atria and ventricles, it is referred to as AV reentrant tachycardia. The less common type of AV reentrant tachycardia (Figure 3C) involves a circuit that travels forward from the atria through the accessory pathway and backward through the AV node.

Another type of tachycardia that can be seen in patients with accessory pathways is a chaotic irregular beating of the upper chambers of the heart called atrial fibrillation. If a patient with an accessory pathway develops atrial fibrillation and if that particular

accessory pathway is capable of rapid electric conduction, this can lead to an extremely rapid pulse rate, which can be dangerous.

What is Wolff-Parkinson-White Syndrome?

Wolff-Parkinson-White syndrome (WPW) is the combination of accessory pathway activation seen on an ECG (delta waves) and episodes of tachycardia. It was first described in 1930 by Louis Wolff, Sir John Parkinson, and Paul Dudley White. Along with a delta wave, patients have a shorter time between the conduction of an impulse from the atrium to the ventricle, referred to as a short PR interval (see the ECG in Figure 2).

What is described above is called a preexcitation or WPW pattern. The

presence of a pattern does not necessarily mean that the patient will experience WPW syndrome. The WPW pattern will be seen in about 0.2% of the general population. Of those patients with the WPW pattern, a minority will experience tachycardia and be defined as having WPW syndrome. WPW can be associated with Ebstein anomaly, a heart defect in which the valve connecting the right atrium and ventricle (tricuspid valve) is abnormally formed and placed lower than normal in the right ventricle. However, in most patients, WPW is not related to any other heart abnormality. It can occur at any age, is often first noted in childhood, but may not be diagnosed until adulthood in some patients. Symptoms of WPW syndrome are usu-



ally abrupt and may include palpitations, chest discomfort, and occasionally fainting.

On very rare occasions (less than 0.1% of the time), a patient with WPW can experience sudden cardiac death that results from the development of a chaotic irregular beating in the upper chambers of the heart called atrial fibrillation with rapid conduction down an accessory pathway (Figure 3B) leading to an extremely rapid pulse that can lead to cardiac arrest. Fortunately, this is a rare event in patients with WPW, and there are certain factors that a physician can often identify ahead of time to risk stratify patients with WPW.

Treatment

Treatment of WPW must be individualized. For patients who have only a

documented WPW pattern on their ECG but no symptoms and no documented tachycardia, simple conservative observation may be appropriate. When symptoms or documentation of arrhythmias exists, a catheter-based electric evaluation of the heart called an electrophysiology study may be offered. This usually results in elimination of the accessory pathway with cauterization delivered through the catheter called radiofrequency ablation. This will also eliminate the WPW pattern on the ECG. On rare occasions, WPW syndrome may be treated with antiarrhythmic medications, although most patients opt for the catheter ablation procedure because it may be curative and eliminate the need for lifelong medication therapy.

Conclusions

WPW syndrome results from tachycardia associated with an accessory pathway. The WPW pattern is diagnosed by a delta wave and/or short PR interval on an ECG. Once symptomatic, patients can be treated with catheter ablation or can try medications to control their symptoms. Management of WPW syndrome should be individualized, and treatment decisions should be carefully discussed with your doctor.

Acknowledgment

We would like to thank Jennifer Cody for her assistance with the preparation of this article.

Disclosures

None.