



## Arrhythmogenic Right Ventricular Dysplasia/Cardiomyopathy

Kathleen Gear, RN; Frank Marcus, MD

The heart is a 4-chambered pump that propels blood simultaneously to the lungs and the rest of the body by means of coordinated muscular contraction. Various diseases can affect the heart muscle and cause it to become weak, thus decreasing its ability to pump blood adequately. Disease that weakens the heart muscle is called cardiomyopathy. Some causes of cardiomyopathy are viral infections of the heart, deposits of harmful substances in or between heart muscle cells, or a degeneration of heart muscle cells due to inherited diseases.

### What Is Arrhythmogenic Right Ventricular Dysplasia/Cardiomyopathy?

Arrhythmogenic right ventricular dysplasia/cardiomyopathy (ARVD/C) is a cardiomyopathy that primarily affects the heart muscle in the right ventricle. Damaged muscle is replaced by fat and/or scar tissue (Figure) in a spotty or diffuse process that starts on the outside surface of the right ventricle and replaces the heart muscle cells that die prematurely. This in turn can interfere with the normal smooth sequence of electrical activity that causes the heart muscle to contract and can lead to heart irregularities. In the lower

chambers of the heart, this disorganized electrical activity can result in irregular heartbeats called ventricular premature beats, which are perceived by the individual as palpitations. If the palpitations occur repetitively, the heart can beat too rapidly to permit adequate filling and contraction, resulting in a rhythm called ventricular tachycardia or ventricular fibrillation, both of which can cause fainting or even sudden death. As the disease progresses, degeneration of the muscle in the right ventricle can spread. The weakened muscle will stretch, producing an enlarged right ventricle. Blood can back up in the veins, resulting in congestion of the liver and swelling of the legs and other organs. This condition is called right heart failure and may occur many years after the disease process begins.

### What Are the Clinical Features of ARVD/C?

Individuals with ARVD/C may appear to be in good health. In fact, there seems to be a disproportionate number of patients who have routinely engaged in vigorous or competitive athletic activity. Participation in competitive athletics has been linked to an earlier presentation of the signs and

symptoms of ARVD/C. It affects men more frequently than women and is usually discovered between the second and fourth decade of life, but rarely before puberty. The first symptoms may be palpitations or fainting. Sudden death is a rare first manifestation. Symptoms often are worse during or immediately after vigorous exercise. Right heart failure is an uncommon initial finding. Both right and left heart failure may occur as the disease progresses, particularly in older individuals.

### Genetic Aspects of ARVD/C

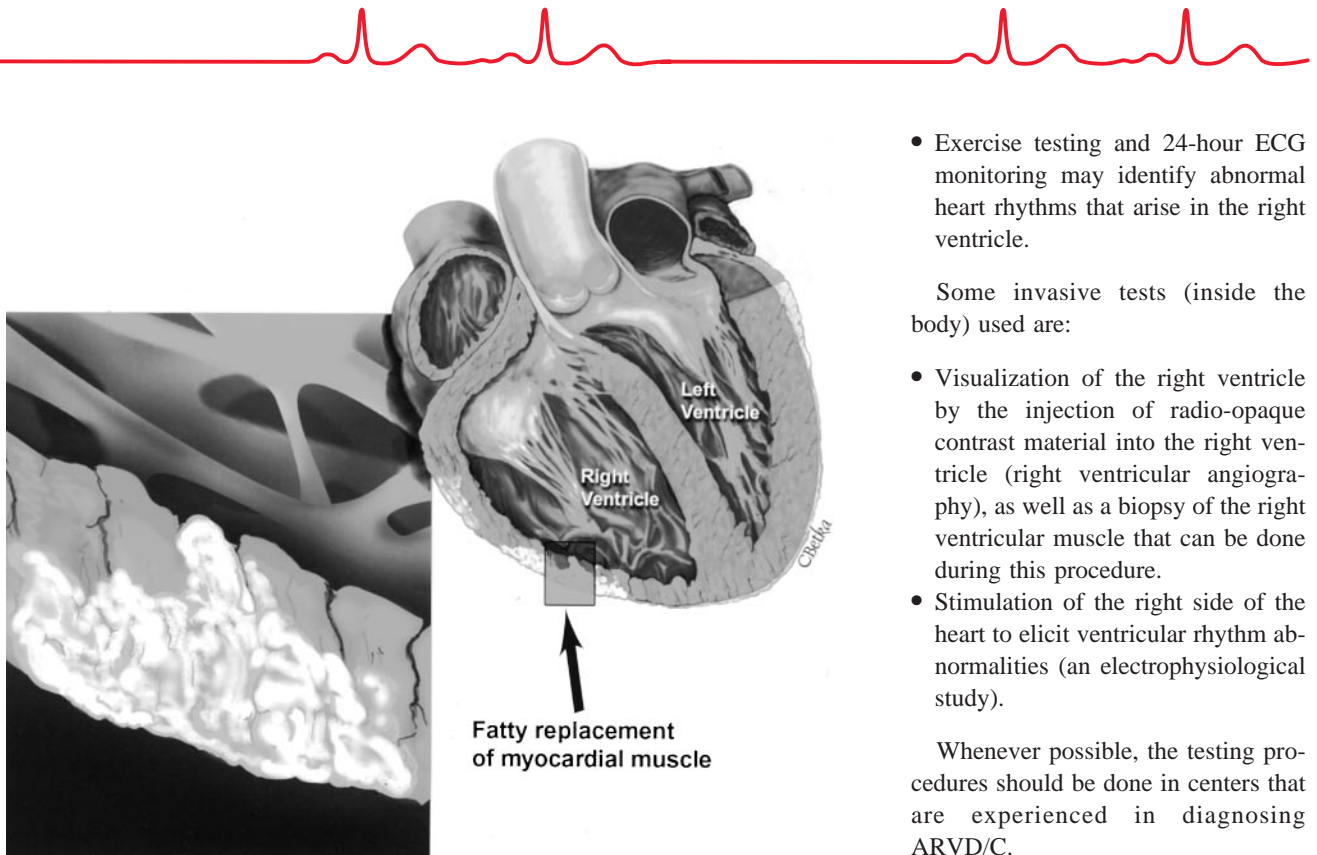
ARVD/C has been found to be genetic in 30% to 50% of individuals and is transmitted from one affected parent to a child as a dominant disorder. If either parent has ARVD/C, each child has a 50% chance of inheriting the disease. In one unusual form, Naxos disease, the condition is transmitted as a recessive form, and the genetic mutation is inherited from both parents. Seven chromosomes have been identified that have areas or gene loci that have been linked to ARVD. Within these chromosomal loci are genes that provide the DNA code to program cellular structure and function. These areas are being investigated to find either a mis-

From the University of Arizona Sarver Heart Center, Department of Medicine, Section of Cardiology, Tucson, Ariz. Correspondence to Kathleen Gear, RN, or Frank Marcus, MD, The University of Arizona Sarver Heart Center, Department of Medicine, Section of Cardiology, 1501 N Campbell Ave, Rm. 5153, Tucson, AZ 85724-5037. E-mail kgear@email.arizona.edu or fmarcus@email.arizona.edu (Circulation. 2003;107:e31-e33.)

© 2003 American Heart Association, Inc.

Circulation is available at <http://www.circulationaha.org>

DOI: 10.1161/01.CIR.0000053943.38763.70



An illustration of fatty replacement of cardiac muscle within the right ventricular wall.

placed, missing, or altered protein within a gene that would program abnormal function or structural development in the right ventricular wall and cause ARVD/C.

### How Is ARVD/C Diagnosed?

ARVD/C is diagnosed by a combination of abnormalities of the heart's structure and rhythm. More than one diagnostic test is necessary to detect these abnormalities and produce a definite diagnosis. Several noninvasive (outside of the body) tests can be used.

- An electrocardiogram (ECG) can show the changes in the electrical pattern that represents the recharge of the heart, known as the T wave. In ARVD/C, the T waves recorded from the electrodes on the chest may be in the opposite direction from normal; they are tipped over instead of being upright. The ECG can also show distinct waves (slurring) of small amplitude that occur before the beginning of the T wave and

indicate prolongation of the duration of the electrical discharge of the heart (epsilon waves).

- If an ECG is recorded simultaneously with palpitations or irregular heartbeat, the ECG pattern can identify these heart rhythm abnormalities as coming from the right side of the heart.
- A high-resolution ECG (signal-averaged ECG) can show prolongation of electrical depolarization of the heart, indicating that there is an area of the heart that may cause heart rhythm abnormalities.
- An echocardiogram will usually show that the right ventricle is enlarged and that there are areas in the right ventricle that do not move normally. It will also document whether or not the left ventricle is normal (or nearly so).
- A magnetic resonance imaging (MRI) study can reveal abnormal contraction patterns and enlargement of the right side of the heart, as well as fatty infiltration of the muscle.

- Exercise testing and 24-hour ECG monitoring may identify abnormal heart rhythms that arise in the right ventricle.

Some invasive tests (inside the body) used are:

- Visualization of the right ventricle by the injection of radio-opaque contrast material into the right ventricle (right ventricular angiography), as well as a biopsy of the right ventricular muscle that can be done during this procedure.
- Stimulation of the right side of the heart to elicit ventricular rhythm abnormalities (an electrophysiological study).

Whenever possible, the testing procedures should be done in centers that are experienced in diagnosing ARVD/C.

### Treatment for ARVD/C

The symptoms of ARVD/C can be treated, but at the present time the disease cannot be cured. Most people who have ARVD/C are able to live normal lives with occasional episodes of abnormal heart rhythms. Patients diagnosed with ARVD/C are advised to avoid vigorous athletic activity because of the strain on the right heart. Arrhythmias can be treated with medications that block the stimulating effects of adrenaline on the heart (beta-blockers) or drugs that have specific properties to prevent abnormal heart rhythms, such as sotalol or amiodarone. Some individuals with ARVD/C will require an implanted cardioverter-defibrillator (ICD) that can automatically diagnose and terminate sustained rapid heart rhythms such as ventricular fibrillation by delivering an electric shock to the heart. For a detailed explanation of how the ICD works, please see the Cardiology Patient Page article by Reiffel and Dizon (*Circulation*. 2002;105:1022–1024). At present, the precise identifi-

## KEY FACTS ABOUT ARDV/C

### Symptoms

- Fainting episodes, especially with exercise
- Episodes of transient or persistent palpitations; may be associated with lightheadedness

### Clues to Diagnosis

- ECG findings
  - T-wave inversions beyond lead V<sub>1</sub>
  - Epsilon waves in leads V<sub>1</sub>–V<sub>3</sub>
  - Abnormal electrical potentials in high-resolution (signal-averaged) ECG
  - Ventricular premature beats with left bundle branch configuration
- Family History
  - Unexplained sudden death in young or middle aged family member(s)

### Treatment

- Antiarrhythmic medications
- ICD
- Heart transplant

cation of individuals with ARVD/C who need this device has not been determined. Electrophysiologists, who are cardiologists who specialize in electrical disorders of heart rhythm, should be involved in the medical care of the patient with ARVD/C. When ARVD/C has progressed to extensive involvement affecting both the right and left ventricles, heart transplantation is an option.

### What Is Being Done to Improve Our Knowledge of This Disease?

The Multidisciplinary Study of Right Ventricular Dysplasia has begun enrolling patients recently diagnosed with ARVD/C into a National Institutes of Health and National Heart, Lung, and Blood Institutes-funded study. The aims are to find the genes for ARVD/C to improve the diagnosis

and treatment of this disease. It is anticipated that when the genetic mutations are found, the mechanisms that lead to the fatty/fibrous replacement of the right ventricular wall muscle will be known. Genetic testing will help determine which family members are affected and which medications can best treat the symptoms of ARVD/C. The ultimate goal is to develop gene therapy to prevent changes in the heart muscle that lead to ARVD/C or to alter the course of the disease favorably. Individuals suspected of having or recently diagnosed with ARVD/C are encouraged to contact the enrolling physicians at the specialized centers that are participating in this multi-center study. For further details, see the web site at <http://www.arvd.org> or <http://www.arvd.com>.

### Acknowledgments

The Multidisciplinary Study of Right Ventricular Dysplasia is supported by grant HL-65594 from the National Heart, Lung, and Blood Institute of the National Institutes of Health, Bethesda, Md.

### Additional Resources

- Marcus FI. Update of arrhythmogenic right ventricular dysplasia. *Card Electrophysiol Rev.* 2002;6:54–56.
- Chalkins H, Marcus F. Arrhythmogenic right ventricular dysplasia. In: Braunwald E, ed. *Harrison's Advances in Cardiology*. New York, NY: McGraw-Hill, 2003:378–383.